PROVA N.1

Trattamento degli aneurismi giganti

PROVA ESTRATTA

Caso Clinico 2

Uomo di 54 anni, da tempo lamenta cervicalgia e nucalgia, esegue i seguenti accertamenti neuroradiologici:

QUESITI:

- Descrivere immagini radiologiche
- Sospetto diagnostico
- Eventuali ulteriori accertamenti necessari
- Trattamento pronosto/consigliato

1) Tac encafalo senza MDC

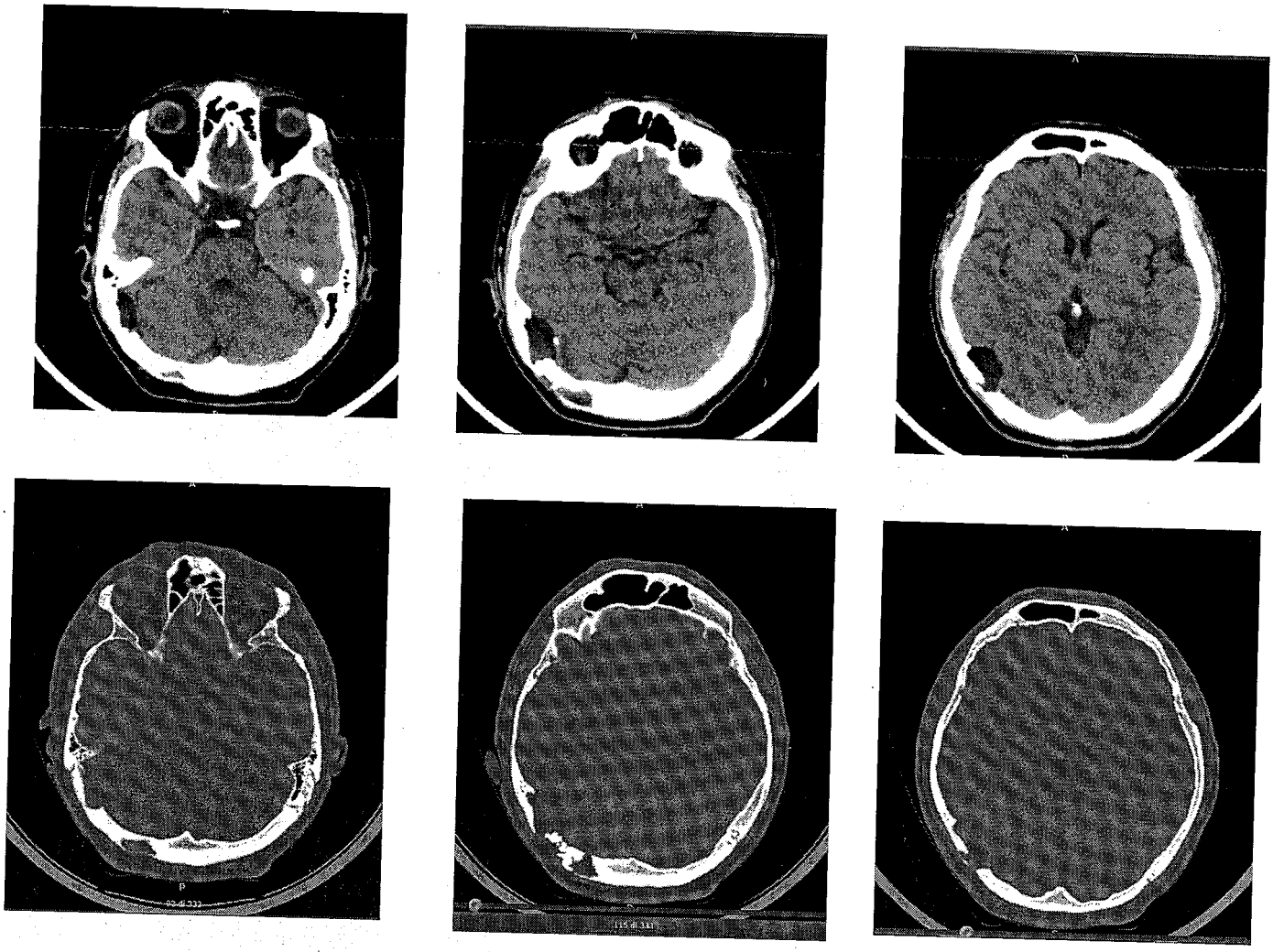

PROVA ESTRATTA

2) RMN encefalo con e senza MDC

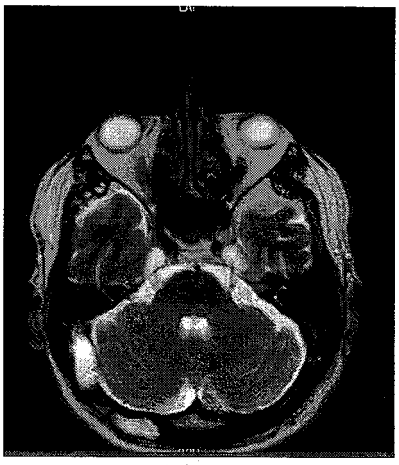

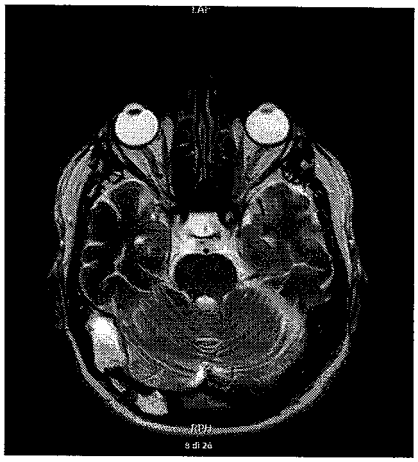

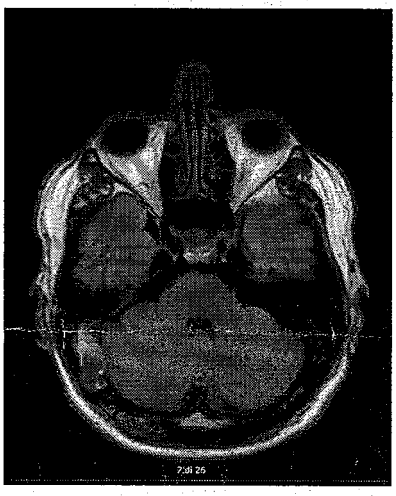

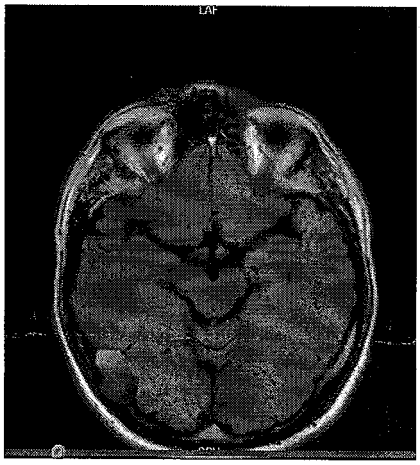

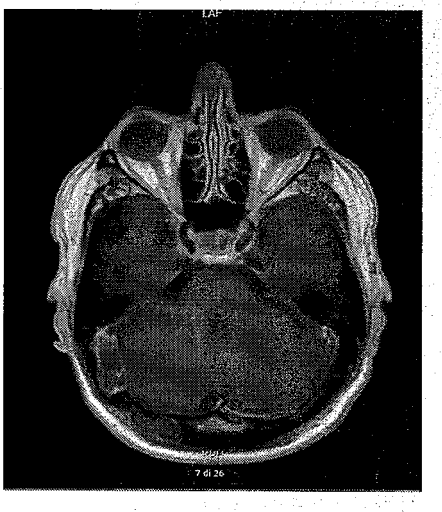

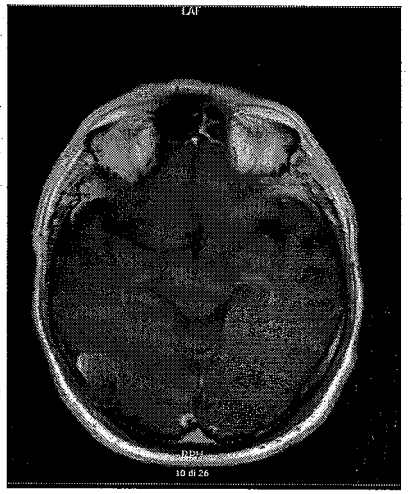

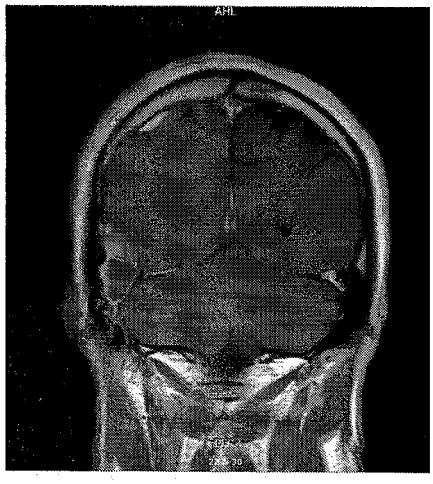

PROVA ESTRATTA